

The Organization of the Frontal Motor Cortex

G. Luppino and G. Rizzolatti

Recent anatomic and functional data radically changed our ideas about the organization of the motor cortex in primates. Contrary to the classic view, the motor cortex does not consist of two main areas, primary and supplementary motor areas, but of a mosaic of cortical areas with specific connections and functional properties.

The caudal sector of the frontal lobe was classically subdivided into two cytoarchitectonic areas, both devoid of granular cells: area 4 and area 6 (Ref. 1; see Fig. 1A). Area 4 and most of area 6 located on the lateral convexity were thought of as a single large functional area: the primary motor cortex or M1. Area 6 located on the mesial cortical surface was considered a second motor area, usually referred to as the supplementary motor area or SMA (Ref. 16; see Fig. 1B).

A recent series of anatomic and functional studies showed that this picture of the agranular frontal cortex (henceforth referred to as the motor cortex) is too simplistic. First, Brodmann's area 4 is functionally distinct from area 6. Thus the classic view of a large M1 that encompasses both area 4 and lateral area 6 is untenable. Second, area 6 is not homogeneous but rather formed by a multiplicity of anatomic areas. Third, these various motor areas have different afferent and efferent connections and, as shown by physiological evidence, appear to play different functional roles in motor control.

Modern subdivisions of the agranular frontal cortex of the monkey are shown in Fig. 1, C and D. The first (Fig. 1C) is based (mostly) on the functional properties of the various parts of the motor cortex; the second, proposed by Matelli et al. (Refs. 7 and 8; see Fig. 1D) is based on cytoarchitectonic and histochemical data, as well as on the functional and hodological properties of the various sectors of the motor cortex. The nomenclature adopted by Matelli et al. derives from von Economo (2). It indicates, however, the various frontal areas with arabic numbers. Thus each frontal area of the figure is referred to with the letter F (frontal), but, unlike in the von Economo nomenclature, it is further specified by a number.

If one compares this parcellation with the classic map of Brodmann, the following picture emerges. F1 basically corresponds to area 4, whereas, as far as area 6 is concerned, each of its three main sectors (the mesial, the dorsal, and the ventral) is formed by a caudal and a rostral subdivision. Seven areas, therefore, form the agranular frontal cortex. In this review, we will outline some principles for subdividing the various frontal motor areas and will briefly discuss their main functional properties. For more details and a review of the literature, see Rizzolatti et al. (13).

Basic differences and grouping of the various frontal motor areas

General considerations. Modern neuroanatomic techniques showed that each frontal motor area has a specific pattern of anatomic connections. When this pattern is closely examined and the functional properties of the areas connected with one another are considered, it emerges that the various frontal motor areas can be grouped into two major classes: 1) areas that transform sensory information into motor commands and 2) areas that are involved in controlling sensory-motor transformation. This picture is certainly partial and does not cover all of the processes mediated by the frontal motor areas, such as associative motor learning, imitation, or recognition of actions made by other individuals. Yet it gives a schema for understanding the basic cortical motor area organization.

Connections with the spinal cord. Corticospinal projections originate from a large frontoparietal territory, comprising, in the frontal lobe, area 4 and the caudal part of area 6. This frontal territory basically corresponds to Woolsey's areas M1 and SMA. The origin of the corticospinal tract and its termination into various segments of the spinal cord were recently reanalyzed in great detail by Strick and coworkers (4, 5). These new data, mapped on the subdivision of the motor cortex presented in Fig. 1D, show that the corticospinal tract originates from the caudal motor areas, that is from F1, F2, F3, and parts of F4 and F5. An important difference between corticospinal projections originating from F1 and those arising from the other frontal motor areas consists in their different terminal territory in the spinal cord. Fibers originating from F1 end in the intermediate region of the spinal cord (laminae VI, VII, and VIII) and in lamina IX (the lamina where motor neurons are located), whereas those originating from the other frontal motor areas mostly terminate in the spinal cord intermediate region (see Ref. 11). This different anatomic organization has, obviously, a functional counterpart. The interpretation we propose is that spinal projections from F2, F3, F4, and F5 activate preformed medullar circuits. They determine the global frame of the movement. In contrast, projections originating from F1, by ending directly on motor neurons, break innate synergies and in this way determine the fine morphology of the movement. It is interesting to note that F2, F3, F4, and F5 all send connections to F1 as well. These data indicate that, although F1 is the only motor area provided with a rich direct access to the motor neuron pools, all of the caudal areas are involved in movement execution, both directly and via F1.

G. Luppino and G. Rizzolatti are in the Institute of Human Physiology, University of Parma, Via Volturno 39, I-43100, Italy.

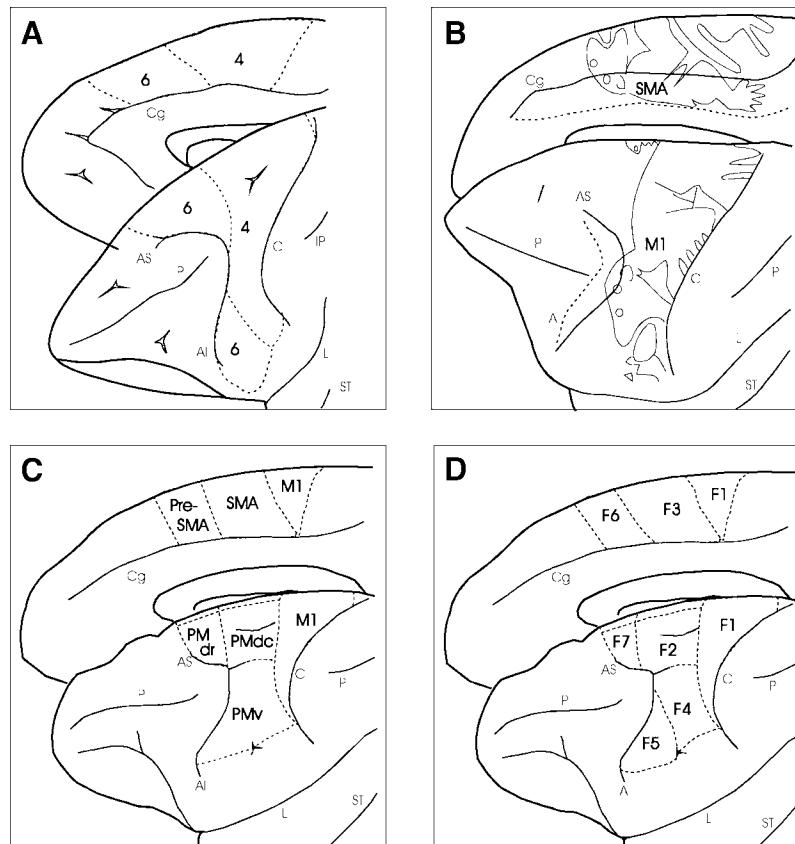


FIGURE 1. Comparative view of some of the proposed subdivisions of the agranular frontal cortex of the monkey. *A*: cytoarchitectonic map of Brodmann (1); *B*: functional map of Woolsey et al. (16); *C*: modern, functional subdivision; *D*: histochemical and cytoarchitectonic map of Matelli et al. (7, 8). AI, inferior arcuate sulcus; AS, superior arcuate sulcus; C, central sulcus; Cg, cingulate sulcus; IP, intraparietal sulcus; L, lateral fissure; M1, primary motor cortex; P, principal sulcus; PMdc, dorsal premotor cortex, caudal; PMdr, dorsal premotor cortex, rostral; PMv, ventral premotor cortex; SMA, supplementary motor area; ST, superior temporal sulcus.

The organization of the rostral frontal motor areas is radically different. F6 (pre-SMA) and F7 are neither connected with the spinal cord nor with F1. Their descending input terminates in various parts of the brain stem (see Ref. 11). These areas cannot, therefore, control movement directly. They may, obviously, control it indirectly through their subcortical relays. Classic electrical stimulation studies showed that this control concerns essentially global axioproximal movements, such as those responsible for the orienting reaction. However, the pattern of cortical connections of these areas (see below), as well as functional data on F6 neurons, suggests that these areas also have other functions. Particularly interesting among them is that of determining the “when” of a movement, according to the external contingencies and internal motivations (see below).

Cortical input to the motor cortex. Cortical afferents to the frontal motor areas originate from three main regions: the parietal lobe (S1 and the posterior parietal sectors), the prefrontal lobe, and the cingulate cortex. Recent functional evidence indicates that, similar to the motor cortex, the posterior parietal cortex is also formed by a multiplicity of independent areas, each of which appears to deal with specific aspects of sensory information and with specific effectors (Fig. 2). Some of these areas are essentially linked to somatosensory modality (e.g., PE), others to visual modality

(e.g., lateral intraparietal area LIP), and others to both (e.g., PF). Anatomic evidence indicates that the parietofrontal connections are highly specific. Each frontal motor area is the target of different sets of parietal areas and, typically, receives strong afferents from only one of them. In turn, most of the parietal areas tend to project massively to a single motor area. Therefore, the parietofrontal connections form a series of largely segregated anatomic circuits. The functional correlate of this anatomic organization is that each of these circuits appears to be dedicated to a particular sensory-motor transformation, the essence of which is the transformation of a description of the stimuli in sensory terms into their description in motor terms (12, 13). It is important to stress that neural activity associated with motor actions has also been observed in many posterior parietal areas. Thus if one defines as motor neurons a neuron the activity of which correlates with an action, there is no doubt that the posterior parietal cortex should be considered a part of the motor system. On the basis of these and similar considerations, it was recently proposed that the parietofrontal circuits, and not frontal motor areas in isolation, should be considered the functional units of the cortical motor system (13).

Our knowledge of the organization of prefrontal and cingulate areas is much less rich and detailed than that of the parietal cortex. It is, however, generally assumed that these

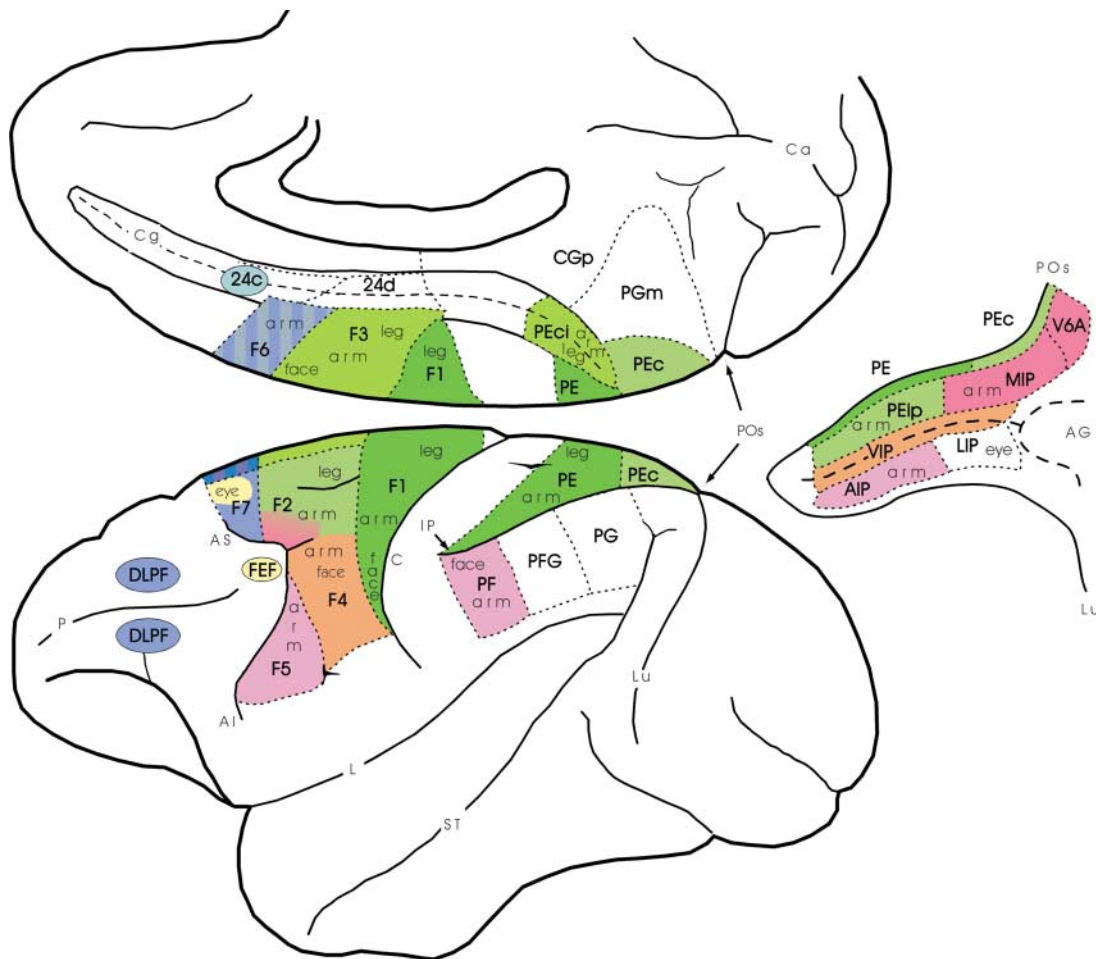


FIGURE 2. Mesial and lateral views of the macaque brain showing the cytoarchitectonic parcellation of the frontal motor cortex and the location of other cortical regions or areas cited in the text. Areas buried within the intraparietal sulcus are shown in an unfolded view of the sulcus. For the nomenclature and definition of motor, posterior parietal, and cingulate areas see Rizzolatti et al. (13). On the basis of the available data, the various body part representations in the motor and parietal cortices are also reported. Single motor areas and their major source of cortical afferents are indicated with the same color. Colors in the green range indicate motor cortex that is mostly the target of somatosensory information; colors in the red range indicate motor cortex that is the target of either visual or visual and somatosensory information; colors in the blue range indicate motor cortex with predominant prefrontal and/or cingulate afferents. AG, annectant gyrus; Ca, calcarine fissure; CGp, posterior cingulate cortex; DLPF, dorsolateral prefrontal cortex; FEF, frontal eye field; Lu, lunate sulcus; POs, parieto-occipital sulcus.

regions are not involved in the analysis of sensory stimuli but rather play a role in “higher-order” functions such as “working memory,” temporal planning of actions, and motivation.

If one now compares the cortical connections of the frontal motor areas giving origin to the corticospinal tract (F2, F3, F4, and F5) with those that do not (F6 and F7), it appears that the former are richly connected with the parietal lobe, whereas the latter are linked with the prefrontal and cingulate cortices. The parietal afferents to F6 and F7 correspond roughly to 1 and 10%, respectively, of their total cortical input, in contrast to ~30 and 20% to F2 and F3. Table 1 summarizes the sources of predominant and additional cortical afferents to each motor area. The intrinsic motor area connections are not included.

From these merely anatomic considerations, it is clear that the functions of the caudal and rostral frontal motor areas ought to be different. Caudal areas elaborate, together with parietal areas, sensory information and transform it into a motor representation. Rostral areas convey inputs to the caudal ones concerning motivation, long term plans,

and memory of past actions. On the basis of this information, the motor representations are either implemented or remain as potential actions that may be either canceled or implemented later, when other contingencies allow it. With this general schema in mind, in the following sections we will briefly review the available evidence on the functions of the various frontal motor areas.

Mesial area 6

Mesial area 6 is cytoarchitectonically formed by two areas: F3 or SMA proper and F6 or pre-SMA (Fig. 1, C and D). Classically, mesial area 6 was considered to be coextensive with the so-called SMA, defined by Woolsey with the use of gross electric stimulation (Fig. 1B). Its functions were considered to be essentially executive. The most accepted view was that SMA collaborated with the primary motor cortex in movement execution, especially for proximal and axial movements. Later, experiments in monkeys and humans gave conflicting results on the possible role of SMA

TABLE 1. Predominant and additional cortical connections of the motor areas in the macaque monkey

Motor Areas	Predominant Connections	Additional Connections
F1	PE	SI
F2	PEc, PEip, MIP	V6A, PFG, CGp
F3	PEci, 24d	PE, SII, SI, PFG
F4	VIP	PF, PEip, SII
F5	AIP, PF	PFG, SII
F6	DLPF, 24c	PFG, PG
F7	DLPF	PGm, V6A, CGp
F7 (SEF)	FEF	DLPF, LIP

For the nomenclature of motor, posterior parietal, and cingulate areas, see Ref. 13 and Fig. 2.

in motor control. Some data appeared to confirm an executive role of SMA in movement, whereas others favored what was called a “supramotor” role of SMA, that is a role in those processes that precede the actual movement execution. The discovery that, in monkeys, mesial area 6 is composed of two distinct areas (Ref. 6; see also Ref. 14) was crucial in reconciling these apparently conflicting results.

Experiments in which mesial area 6 of the monkey was systematically explored with intracortical microstimulation showed that F3 is electrically excitable with low-intensity currents and contains a complete body movement representation. Evoked movements mainly involved proximal and axial muscles and, typically, a combination of different joints, even at the minimal effective current intensity. Distal movements, when evoked, were often observed in combination with the proximal ones. Single unit recordings showed that F3 neurons frequently have somatosensory responses. When neurons were studied during active movements, it was found that the relation between the discharge and the movement varied from one neuron to another, but in most neurons it was time-locked with the movement onset (movement-related activity). Hodological studies demonstrated that F3 is the source of dense, topographically organized corticospinal projections. Connections with other motor areas are also topographically organized and link F3 with F1 and with areas F2, F4, and F5. F3 is also strongly connected with a caudal and dorsal part of area 24. This subsector of area 24, termed 24d, roughly corresponds to what is also referred to as the caudal cingulate motor area and, like F3, is characterized by dense corticospinal projections and connections with F1. Finally, F3 is the target of strong parietal afferents mostly originating from area PEci, located in the caudalmost part of the cingulate sulcus and also referred to as the supplementary sensory area, and from areas SI and SII.

In contrast to F3, F6 is weakly excitable with intracortical microstimulation. Motor responses can be evoked from it only with rather high current intensities, and, typically, they consist of slow and complex movements restricted to the arm. Single-neuron recordings showed that in F6, unlike F3, visual responses are common, whereas the somatosensory

ones are rare. When tested during active arm movements, F6 neurons show a long leading activity during preparation for movement, and some of them fire in relation to a redirection of an arm movement to a direction opposite to one previously rewarded (shift-related activity). Other experiments demonstrated that F6 neurons might be excited or inhibited when objects, moved toward the animal, enter into its reaching distance and, therefore, appear to be modulated by the possibility of grasping an object. F6 is the source of a modest corticospinal projection, has no direct connection with F1, and is connected with all of the caudal and rostral premotor areas. Parietal afferents to F6 are few and originate from visual areas of the inferior parietal lobule. On the contrary, F6 is a target of strong afferents originating from both the dorsal and ventral parts of the dorsolateral prefrontal cortex and is the only motor area target of rich afferents from the cingulate area 24c and from the cingulate gyrus.

Altogether, these data indicate that of the two mesial areas, only F3 has characteristics similar to those of SMA as classically defined. It was suggested that F3 may play an important role in the control of posture and, in particular, in postural adjustments preceding voluntary movements. In contrast, F6 appears to be a nodal point in transmitting limbic and prefrontal information to other motor areas. Functionally, F6 appears to be related to selection and preparation of movement and, in particular, to the control of actions in terms of decision of when to start a movement, according to external contingencies and motivation. For these properties, it appears to play an important role in the organization of complex movement sequences.

There is clear evidence that, as in the monkey classical SMA, the human mesial area 6 is also formed by two distinct areas. They are usually referred to as SMA proper and pre-SMA. A large body of data, coming from brain imaging studies, indicates that although the SMA proper is activated during the execution of a variety of motor tasks, including single body part movements, the pre-SMA requires complex motor tasks to be activated (for a review of the literature, see Ref. 10). The human SMA proper and pre-SMA are considered the homologues of monkey F3 and F6, respectively.

Dorsal area 6

This sector of area 6, frequently referred to as the dorsal premotor cortex (PMd), is formed by two areas: area F2 and area F7 (Fig. 1D). F2 is electrically excitable and has a rough somatotopic organization, with a leg and an arm representation located dorsal and ventral to the superior precentral dimple, respectively. In the past, this area was considered to be part of Woolsey's M1. Possibly for this reason, most of the functional studies of F2 have been focused on the motor properties of its neurons. Thus not much is known about F2 sensory properties. Available evidence indicates, however, that many F2 neurons respond to somatosensory stimuli and in particular to the proprioceptive ones. Recent observations from our laboratory showed that in F2 there are also neurons driven by three-dimensional visual stimuli. These neurons are located essentially in its rostral and ventral part. Motor

properties of F2 neurons were mostly studied by employing visually instructed delay motor tasks. In these tasks, a motor response (very often an arm movement) is performed with a delay after the appearance of a visual stimulus that instructs the monkey on the particular movement requested. Some F2 neurons discharge in association with the movement onset (movement-related activity); others become active during the delay period when the monkey is waiting for the go signal (set-related activity). Finally, others discharge at the appearance of the instructing stimulus (signal-related activity). These data indicate that F2 is not simply involved in motor execution but also plays a role in some aspects of motor preparation (see Ref. 15). F2 is a source of corticospinal projections and is connected with F1. Parietal afferents are very rich and differentially distributed within this area. That part of F2 that is located around the superior precentral dimple is a major target of areas PEc and PEip. These two areas are involved in higher-order somatosensory elaboration. In contrast, the ventral and rostral part of F2 (the part where the visually responsive neurons are located) is a major target of areas MIP and V6A, two areas in which neurons have visual, somatosensory, or both visual and somatosensory responses.

Much less is known about the functional properties of F7, with the exception of its dorsal part, which contains the supplementary eye field (SEF). The SEF is an oculomotor field that can be identified with intracortical microstimulation and that, anatomically, is richly connected with the frontal eye field. The remaining part of F7 is scarcely excitable and has been the object of few functional studies. Some F7 neurons have visual responses even when the stimulus is not instructing a subsequent movement. Others have visual responses when the location of the stimulus matches the target of an arm movement. F7 is not a source of corticospinal projections and is connected with F2 and F6. Parietal afferents are modest and mostly originate from area PGm, an area located on the mesial wall of the hemisphere. PGm is connected with PG and with extrastriate visual areas. In contrast to the poverty of parietal afferents, F7 is a target of strong projections from the dorsal part of the dorsolateral prefrontal cortex. A weak input to F7 also originates from the rostral cingulate cortex.

Together, these data indicate that the areas forming the dorsal area 6 are involved in different aspects of movement control. F2 appears to be involved in planning and executing arm and leg movements on the basis of somatosensory information as well as visual information. F7 could be involved in coding object locations in space for orienting and coordinated arm-body movements.

Another higher function of F7 (and of the dorsal area 6 in general) is suggested by lesion experiments. Damage to dorsal area 6 (F7, but extending also into F2) in monkeys trained to perform goal-directed movements in response to arbitrary external stimuli (conditional association motor learning) severely affects the performance of the animal in previously learned motor association tasks and prevents new learning (see Ref. 9). It is possible, therefore, that dorsal area 6 is involved in motor control by retrieving from memory the motor response most appropriate to the context.

Ventral area 6

Ventral area 6, frequently referred to as ventral premotor cortex (PMv), is formed by two areas: F4 and F5 (Fig. 1D). F4 is electrically excitable. It contains a representation of arm, neck, and face movements. Like F2, it was considered in the past to be part of Woolsey's M1. Some F4 neurons are active in association with simple movements; others discharge during the execution of specific actions, such as movements directed toward the mouth, the body, or toward particular space locations. Almost all F4 neurons are active in response to sensory stimulation. Half of them respond to somatosensory stimuli, whereas the other half are bimodal, responding to both visual and somatosensory stimuli. The bimodal neurons have tactile receptive fields (RFs) located on the face, the body, or the arms. The visual RFs are three-dimensional, limited in depth to the peripersonal space, and located around the tactile RFs. Visual responses are very often selective for

“F7 could be involved in coding object locations in space for orienting and coordinated arm-body movements.”

stimuli moving toward the tactile RFs. For the majority of F4 neurons, the spatial location of the visual RFs does not change with eye movement, remaining anchored to the tactile RFs. These findings indicate that the visual RFs of F4 neurons code space using an egocentric, body part-centered frame of reference. This system is particularly suitable for organizing arm and head movements in space. F4 is the source of corticospinal projections and is directly connected with F1. Nonmotor connections are almost exclusively related to the posterior parietal cortex. In particular, F4 is a major target of an area located along the fundus of the intraparietal sulcus and called the ventral intraparietal (VIP) area. Area VIP shares many functional properties with F4. Also in this area there are bimodal, visual, and tactile neurons, most of them centered on the face and, as in F4, visual RFs are in register with the tactile ones and limited to the peripersonal space. In at least one-third of these neurons, visual RFs appear to be coded in egocentric coordinates.

F5 is electrically excitable and contains a movement representation of the hand and the mouth. F5 neurons typically code goal-directed motor acts, such as grasping, holding, tearing, or manipulating objects. Their firing is correlated with the action execution and not with the individual movements forming it. Most of the “grasping neurons” code specific types of hand prehension, such as precision grip (thumb and index finger opposition), whole hand prehension, and finger prehension. A considerable part of F5 neurons respond to visual stimuli. Visually responsive F5 neurons are subdivided into two classes. Neurons of the first class (canonical neurons) discharge to the presentation of three-dimensional objects even when no action on the object is requested. These responses are most likely to be the result of a “pragmatic” representation of the object, in which the object's

intrinsic properties (size, shape, and orientation) are coded to select the most appropriate way to grasp it. Visually responsive neurons of the second class (mirror neurons), although similar in their motor properties to the canonical neurons, have markedly different visual properties. They are not activated by simple observation of objects but discharge selectively when the monkey observes another individual performing an action similar to that encoded by the neuron (3). These findings suggest an important cognitive role for the motor cortex: that of representing actions internally. This internal representation, when evoked by actions made by others, could be involved in two related functions: action recognition and action imitation. F5 receives a modest projection from the ventral part of the dorsolateral prefrontal cortex. Its main connections are with a parietal area located within the intraparietal sulcus, the anterior intraparietal area (AIP), and with area PF. AIP neurons have functional properties similar to those of the canonical F5 neurons. They have motor responses coding selective hand manipulation and grasping movements and visual responses selective for the physical characteristics of the objects.

Together, these data indicate that the two ventral area 6 areas play a crucial role in the visual guidance of goal-directed arm movements. In particular, F4, together with VIP, appears to be part of a parietofrontal circuit involved in encoding peripersonal space and in transforming object locations into appropriate movements toward them. F5, together with AIP, forms a circuit that appears to be crucially involved in the visual guidance of hand grasping and manipulation movements. This last circuit is a paradigmatic example of a “dedicated” parietofrontal circuit. Recent experiments showed that inactivation of either F5 or AIP produces a severe deficit of the hand shaping that usually precedes object grasping. As a consequence, there is a mismatch between the object shape and finger posturing, even in the absence of pure motor deficits.

Conclusions

Until recently, the motor cortex was considered to play essentially an executive role in motor control. Its role was that of a passive executor of motor commands that originate from associative areas of the parietal and frontal cortices. These last areas were the truly responsible for higher-order cognitive functions. The data here reviewed provide a new picture of the way in which voluntary movement is controlled by the cortical motor system. The motor cortex is formed by a mosaic of independent motor areas characterized by unique sets of connections with parietal, prefrontal, and cingulate cortices and involved in specific aspects of motor planning and execution. In this view, sensory-motor

transformations are the result of a strict cooperation between parietal and motor areas, linked by strong, reciprocal connections and forming largely segregated circuits. Each of these circuits is dedicated to a specific aspect of sensorimotor transformation, in which motor and sensory information are fully integrated at both the parietal and motor levels and may then be considered the functional unit of the cortical motor system. Furthermore, some of the motor areas, by virtue of specific connections with prefrontal and cingulate areas, are involved in higher-order aspects of motor control related to motivation, memory, and temporal planning of motor behavior as well as in “cognitive” functions.

References

1. Brodmann K. *Vergleichende Lokalisationslehre der Groshirnrinde*. Leipzig, Germany: Barth, 1925.
2. Von Economo C and Koskinas GN. *Die Cytoarchitektonik der Hirnrinde des erwachsenen Menschen*. Wien, Germany: Springer, 1925.
3. Gallese V, Fadiga L, Fogassi L, and Rizzolatti G. Action recognition in the premotor cortex. *Brain* 119: 593–609, 1996.
4. He SQ, Dum RP, and Strick PL. Topographic organization of corticospinal projections from the frontal lobe: motor areas on the lateral surface of the hemisphere. *J Neurosci* 13: 952–980, 1993.
5. He SQ, Dum RP, and Strick PL. Topographic organization of corticospinal projections from the frontal lobe: motor areas on the medial surface of the hemisphere. *J Neurosci* 15: 3284–3306, 1995.
6. Luppino G, Matelli M, Camarda R, Gallese V, and Rizzolatti G. Multiple representations of body movements in mesial area 6 and the adjacent cingulate cortex: an intracortical microstimulation study. *J Comp Neurol* 311: 463–482, 1991.
7. Matelli M, Luppino G, and Rizzolatti G. Patterns of cytochrome oxidase activity in the frontal agranular cortex of macaque monkey. *Behav Brain Res* 18: 125–137, 1985.
8. Matelli M, Luppino G, and Rizzolatti G. Architecture of superior and mesial area 6 and of the adjacent cingulate cortex. *J Comp Neurol* 311: 445–462, 1991.
9. Passingham RE. *The Frontal Lobe and Voluntary Action*. Oxford, UK: Oxford University Press, 1993.
10. Picard N and Strick PL. Motor areas of the medial wall: a review of their location and functional activation. *Cereb Cortex* 6: 342–353, 1996.
11. Porter R and Lemon R. *Corticospinal Function and Voluntary Movement*. Oxford, UK: Clarendon, 1993.
12. Rizzolatti G, Fogassi L, and Gallese V. Parietal cortex: from sight to action. *Curr Opin Neurobiol* 7: 562–567, 1997.
13. Rizzolatti G, Luppino G, and Matelli M. The organization of the cortical motor system: new concepts. *Electroencephalogr Clin Neurophysiol* 106: 283–296, 1998.
14. Tanji J. New concepts of the supplementary motor area. *Curr Opin Neurobiol* 6: 782–787, 1996.
15. Wise SP, Boussaoud D, Johnson PB, and Caminiti R. Premotor and parietal cortex: corticocortical connectivity and combinatorial computations. *Annu Rev Neurosci* 20: 25–42, 1997.
16. Woolsey CN, Settlage PH, Meyer DR, Sencer W, Pinto Hamuy T, and Travis AM. Patterns of localization in precentral and “supplementary” motor areas and their relation to the concept of a premotor area. *Res Publ Assoc Nerv Ment Dis* 30: 238–264, 1952.